PRACTICE LIMITED TO RHEUMATOLOGY
Diplomate American Board of
Internal Medicine
Diplomate American Board
of Rheumatology

Director, Arthritis and
Connective Tissue
Disease Section,
MONMOUTH MEDICAL CENTER
LONG BRANCH, NEW JERSEY
Telephone (908) 870-3133
(732)

ARTHUR E. BRAWER, M.D., P.A.
170 MORRIS AVENUE, SUITE B
LONG BRANCH, NEW JERSEY 07740-6698

Sept. 11, 1996

DISCLOSURE

Dr. Brawer has examined patients at the request of plaintiffs' attorneys, has received compensation from plaintiffs' attorneys for these examinations, and has testified at depositions and at trial on behalf of plaintiffs involved in silicone gel breast implant litigation.

SILICON AND MATRIX MACROMOLECULES: NEW RESEARCH OPPORTUNITIES FOR OLD DISEASES FROM ANALYSIS OF POTENTIAL MECHANISMS OF BREAST IMPLANT TOXICITY

ARTHUR E. BRAWER, M.D.
DEPARTMENT OF MEDICINE
DIVISION OF RHEUMATOLOGY
MONMOUTH MEDICAL CENTER
THIRD AND PAVILION AVENUES
LONG BRANCH, NEW JERSEY 07740
U.S.A.

Corresponding author:
Arthur E. Brawer, M.D.
170 Morris Avenue
Long Branch, New Jersey 07740
U.S.A.
(732) ~~(908)~~ 870-3133
FAX: ~~(908)~~ (732) 222-0824

Address for reprints:
Arthur E. Brawer, M.D.
170 Morris Avenue
Long Branch, New Jersey
07740 U.S.A.

KEY WORDS: SILICON; MATRIX MACROMOLECULES; BREAST IMPLANTS; SILICONE

Publication date: June, 1998

ABSTRACT

An understanding of the normal and essential integration of the element silicon in biosystems, as well as knowledge of its fundamental chemistry, are crucial to understanding its role in health and disease. Modern organosilicon chemistry, based in part on the artificial silicon-carbon bond, coincided with the emergence of biomaterials and bioengineering fields fifty years ago, and was thought to be a fortunate coincidence due to conventional wisdom that high molecular weight polymeric siloxanes were chemically and biologically inert. These concepts have been challenged by reports of silicone migration and degradation following insertion of gel-filled breast implants, claims of a novel systemic illness appearing in many breast implant recipients, and investigations implicating varied and permeating immunotoxic mechanisms of disease causation by breast devices. The present study develops additional potential pathogenetic ideas based on alterations of cell biochemistry by silicon-containing compounds, and offers correlation of the patients' diverse clinical features with plausable disruption of basic biological processes. This in turn raises new questions concerning everyday environmental exposure, has broad implications for multiple other diseases, can provide alternative directions for future investigative research, and may contribute to the ongoing redefinition of immune dysfunction and inflammation.

Silicon (Si) is the second most abundant element in the earth's upper crust, second only to oxygen (O), to which it is usually bound in nature rather than existing free in its elemental form.[1] Under ordinary circumstances silicon, like carbon, is capable of forming four bonds, and both are known for their ability to polymerize and form network covalent structures.[1,2] However, unlike carbon, silicon does not usually form stable bonds to itself.[1,2] Silica (silicon dioxide, or SiO_2) consists of two double bonded oxygens to silicon, and is found in amorphous and crystalline forms. The amorphous forms include natural and synthetic glasses and fumed fillers in many consumer products.[10] Crystalline silica in the form of quartz is the most abundant mineral in the earth's crust, and is essentially a dehydrated hard igneous rock formed by high temperature and pressure processes.[1] Other forms of crystalline silica include cristobalite and tridymite.[10] Silicates are minerals composed of silicon, oxygen and other ions (K, Na, Ca, Mg, Fe, Al, P, etc.), and are also part of most rocks on the earth's surface.[1,10] Some nonfibrous (crystalline) forms of silicates include feldspar, talc, mica, vermiculite, and bentonite, while fibrous forms include all the asbestos compounds.[1,10]

The upper crust layer above the mantle of the earth consists of igneous rocks, sedimentary rocks, hydrosphere (oceans, ice, rivers, lakes, water vapor), and atmosphere (air).[1] Igneous rocks are rocks which have been formed by a melting process caused by high temperature and pressure. Silicon content in igneous rocks

is very high.[1] The most silicon rich rocks are designated as acidic (e.g., granite, quartz), while those poorer in silicon, which also contain much magnesium and calcium oxide, are designated as basic (e.g., diorite, gabbro). Sedementary rocks consist of three main types: limestone, shale, and sandstone.[1] These contain the common minerals like feldspar and quartz, and also contain dolomite, calcite, and hemotite. The silicon content of sedimentary rocks is also high.[1]

The hydrosphere acts as a link and balance between the igneous rocks and the sedimentary rocks by the natural process of chemical weathering. In this process, silicon in various forms is leached out and transported via rivers and streams from the igneous rocks of the continents to the oceans, where water, carbon dioxide, and hydrochloric acid are added along the way.[1] As the sediments grow in thickness, they sink deeper and deeper into the sea bottom where temperatures increase, mixing with magma occurs, and eventually rise up to the surface forming new mountains and continents. The entire weathering process releases free solid silica which, in the presence of water, produces monosilicic acid:[1]

$$SiO_2 + 2H_2O \longrightarrow Si(OH)_4$$

This is true for any of the forms of silica, amorphous or crystalline.[1] The rate of reaction depends only on the temperature, pressure, and the nature of the solid silica phase. The -OH group attached to silicon is called a silanol. Silicon in

natural waters exists mainly as monosilicic acid.[1] Despite varying concentrations in drinking waters in different municipalities and countries, human serum concentrations of silicon remain the same in the presence of normal renal function.[1,10]

The emergence of silicon metabolizing biological systems 500-600 million years ago, especially in diatoms (unicellular algae), resulted in a drastic alteration of the concentration of dissolved silica in the oceans, which eventually reached a balance.[1] For these organisms silicon was and still is essential for virtually any and all cellular functions, including DNA synthesis, energy production, and cell wall structure.[1] During the subsequent complex and long evolutionary process a choice was made between phosphorus and silicon, and the original primative formation of organic silicate esters gave way to present day sulfate and phosphorate esters.[1] The net result was that the older pathways have long since been abandoned by the higher organisms. Thus, part of the intracellular capability to recycle silicon in this globally crucial and integrated biochemical manner appears to have been lost.

This is not inconsistent with current knowledge that silicon is essential to normal growth and development. It should be noted, however, that the organic derivatives of silicates that have functional significance in man contain silicon bonds linked to oxygen, not carbon.[1] There is a biological need for silicon beginning with embryologic development of connective tissues and subsequently encompassing maintenance of the same.[1,45] It has

been known for over two decades that silicon, calcium, phosphorus, and magnesium accumulate in the mitochondria of osteoblasts before any evidence of extracellular ossification occurs.[1,45] Silicon deficiency in animals causes reduced mineralization of bone, reduced collagen content of bone, reduced skeletal growth, bone deformities, thinner articular cartilage, smaller and less well formed joints, and adverse effects on skin, hair, nails, and mucous membranes.[1,45] Under normal conditions silicon is found in highest concentration in the aorta, trachea, tendons, ligaments, bone, cartilage, skin, dental enamel, cornea, and sclera.[1,10] For these areas and all other connective tissue sites throughout the body, the proteins in the solid phase extracellular matrix containing covalently bound carbohydrates are classified into three categories: glycoproteins, collagens, and proteoglycans. For proteoglycans, the major carbohydrate component is a glycosaminoglycan, which is an unbranched long chain that is highly sulfated and has a motif of a disaccharide repeat.[11] Examples are keratan sulfate, chondroitin sulfate, hyaluronan, dermatan sulfate, heparin, and heparan sulfate. Silicon provides links within and between polysaccharide chains of glycosaminoglycans, and helps link the glycosaminoglycans to their respective proteins.[1,45] Types II and IX collagens are also known to contain bound glycosaminoglycan chains. Glycoproteins are formed when sugars such as mannose, fucose, galactose, sialic acid, and N-acetylglucosamine are linked to proteins in oligosaccharide units.[23] All of these matrix components are adhesives, acting as glues by binding to

each other. Thus, in an extracellular locale, silicon contributes to the architecture, form, strength, and resilience of connective tissues.

The solid phase extracellular matrix is also involved in storing, binding, protecting, and releasing many regulatory agents. All hormones, growth factors, gases, waste disposal, and nutrients must penetrate or pass through the matrix in moving from one tissue or compartment to another. Matrix components can select, inhibit, facilitate, and remove molecules with which they come in contact. For intercellular exchanges of information (e.g., neural transmission), the role of the matrix must be considered.

The classic extracellular matrix macromolecules are chemically similar to macromolecules found on cell surfaces, and as such are integral membrane components as well.[11] The cell membrane bilayer of phospholipids acts as a solvent for integral membrane proteins which can diffuse laterally in this milieu. The attached sugar residues on these proteins are always located on the extracellular side of the plasma membrane.[23] These carbohydrates are information rich molecules, and their diversity and complexity confers a variety of important functional characteristics. Examples in the proteoglycan category include syndecan, aggrecan, decorin, versican, biglycan, and glypican, with known functions as receptors, adhesion molecules, signal transducers, inhibitors, regulators, and epithelial cell layer stabilizers.[11]

Other cell surface proteins are intermittently linked to

glycosaminoglycans and are termed part-time proteoglycans. Examples include thrombomodulin (an endothelial cell membrane proteoglycan that interacts with protein C and thrombin to influence coagulation), betaglycan (receptor for transforming growth factor B), and CD44 (hyaluronan receptor, lymphocyte homing receptor).[11] The CD44 receptor mediates specific adhesion of lymphocytes to high endothelial venules in lymph nodes. It has a wide distribution, and is expressed in brain, medullary thymocytes, B cells, monocytes, mature T cells, fibroblasts, granulocytes, erythrocytes, keratinocytes, and carcinoma cell lines. Some of the solid phase and cell surface proteoglycans are also known to be soluble in the body (i.e., exist in blood or tissue fluids), such as aggrecan, decorin, glypican, hyaluronan, betaglycan, and syndecan. Hyaluronan is involved in varied biologic processes ranging from embryonic development to wound healing. On the cell surface betaglycan enhances signal responsiveness to TGF-B, but in the soluble matrix phase it is an antagonist.

By inference, silicon can be expected to be present in all of the proteoglycan macromolecules discussed so far. Even the basement membrane (cell lamina) is likely to incorporate silicon in its structure. This matrix, which is noncovalently linked to the plasma membrane of most animal cells, is present over most of the surface of muscle cells (smooth, cardiac, and skeletal), fat cells, Schwann cells, and the basal surface of most epithelial cells.[11] The basement membrane contains at least one proteoglycan,

perlecan, which contains the glycosaminoglycan heparan sulfate. The cell lamina is intimately involved with active exchange in and out of the cell, filters and protects the surface of the cell, and provides temporary binding and/or storage of a variety of regulators and growth factors. Signals from the synaptic cell lamina of muscle cause acetylcholine receptor genes to transcribe agrin (which contains three laminin modules). Secretion of agrin results in interaction with proteoglycans, inducing aggregation of the acetylcholine receptors at the neuromuscular junction. Perlecan also interacts with platelet derived growth factor and dampens its stimulation of smooth muscle replication. In the fluid phase heparan sulfate can inhibit fibroblast growth factor binding to fibroblast receptors.

Glycosaminoglycans are also present in secretory granules inside mast cells, the latter of which are found in or around alveoli, bowel mucosa, dermis, nasal and conjunctival mucosa, synovium, blood vessels, and bronchioles.[11] Preformed mediators such as tryptase are stored inside secretory granules bound to heparin, in close proximity to chondroitin sulfate E. Mast cells secrete serglycin, a proteoglycan also made by all other types of hematopoetic cells (including natural killer cells), which stores and protects a variety of agonists with which it is co-packaged. For the mast cell this includes histamine, and when taken in its entirety serglycin clearly in involved in regulating the release and rates of degradation of all sorts of bioactive reagents responsible for inflammation, immune responses, and

coagulation. In this regard it is interesting to note that suppression of natural killer cell activity has been reported in patients with silicone gel breast implant toxicity, with reversal of this dysfunction following explantation.[25]

Glycoproteins are equally pervasive in their functional importance, and mediate many biological recognition processes.[11] Glycoprotein receptors in the cell membrane of platelets are intimately involved in adhesion and activation. Thrombospondin (a glycoprotein found in platelets and other cells) influences fibrin formation and lysis by inhibiting plasmin. Laminin bound to adhesion molecules of endothelial cells is in turn bound to type IV collagen by entactin (a glycoprotein that is a major constituent of basement membranes). Proteolytic fragments of the laminin alpha chain are chemotactic for mast cells. The majority of cell surface receptors mediating endocytosis are transmembrane glycoproteins.[23] Apolipoproteins are glycoproteins that not only solublize lipoprotein constituents but also hold the key function for their metabolic fate by interacting with enzymes and cell membrane receptors. Endothelial cell surface receptors for oxidized LDL are complemented by lipoprotein lipase bound to heparan sulfates. Indeed, the comingling of numerous glycoprotein and proteoglycan molecules on the surface of endothelial cells enables these cells to perform a wide variety of critical physiologic functions by interacting with (1)cellular and soluble blood components, (2)other cells in the vascular wall, (3)solid phase matrix components, and (4)multiple cytokines, the

latter of which can up regulate other adhesion molecules (selectins, integrins, etc.). The carbohydrate binding adhesion molecules known as selectins are similar to the carbohydrate binding proteins of E. coli called lectins, which enable the bacteria to adhere to epithelial cells of the GI tract. This highly preserved evolutionary mechanism forms the basis for some viruses to gain entry into host cells, and for the CD44 ligand. Adhesins are surface molecules expressed by other microorganisms that use the matrix as a substrate to establish infection. As an example, both pneumocystis and aspergillus bind to fibronectin, a glycoprotein that has affinities for collagen, fibrin, heparin, thrombospondin, integrins, and components of bacterial cell walls, and which forms a substrate for repair cells to adhere to in wound healing. During angiogenesis (neovascularization) if anchorage dependent endothelial cell spreading and migration is inhibited, apoptosis is triggered. Apoptosis has recently been reported to occur when anti-cardiolipin antibodies bind to membrane complexes of phosphatidylserine and B_2glycoprotein.[44]

From the preceding discussion it can be appreciated that despite losing its role in energy production and DNA synthesis, silicon biointegration remains quite extensive in that it is intimately involved with macromolecules displaying endless variations of complex overlapping interactions. It also seems logical that silicon (like growth factors, cytokines, hormones, and vitamins) should impact on matrix regulation, contributing to the circuitous observation that the matrix itself is directly and

indirectly involved in feedback on its own production, polymerization, degradation and recycling.

Perhaps one of the most striking facts regarding the biochemistry of silicon is that virtually no silicon-carbon, silicon-hydrogen, or silicon-silicon bonds have been detected in nature.[1,2] But over 50,000 such compounds were synthesized during the last century in many laboratories, and form the basis of modern organosilicon chemistry. These molecules essentially contain organic substituents bound to silicon through the silicon-carbon bond. Common silicon containing products include fluids, oils, rubbers, plastics, resins for impregnation of paper and fabrics, glass, cosmetics, lacquer, paint, varnish, adhesives, sealers, anti-stick agents, anti-foam agents, water repellants, insulation materials, household abrasives, beer, insect repellants, pesticides, insectisides, and other poisons. These latter three items are comparable to strychnine and can cause muscle twitching, convulsions, fever, tremors, respiratory depression, paralysis, and altered coagulation.[1] Other products increase the yield and quality of crops, increase the weight of fowl, increase egg production, serve as food additives (e.g., spices, powdered sugar, dried eggs), coat fruits to prevent bruising, and aid in food processing. Biologically active organosilicon compounds with everyday medical uses are myriad, and include antomicrobials, psychotropic drugs, anticonvulsants, anti-tumor agents, wound and burn ointments, skin coverings to promote faster healing, anti-flatulants, anti-ulcer agents, and allopecia preparations.[1] Some of these products contain silicones and have the ability to

modulate hormonal, endocrinologic, and neurotransmitter functions. Other widespread applications of this technology include intravenous tubing, cardiac pacemaker lead tips, heart valves, cerebrospinal fluid shunt tubing, digital joint arthroplasty prostheses, vitreous replacements, lens implants, contact lenses, syringe lubrication, nasal and mandibular reconstruction devices, dental impression materials, and breast implants. All of the products in this last category are composed of silicones.

The obvious question to be asked, then, as more and more of these products proliferate for routine commercial use is: in which way will living organisms react if they are confronted with artificial organosilicon compounds? The in vivo chemistry evolved by biological systems is different from the chemistry of man's ingenuity. Although chemists have collected a great deal of physical data on the strength, energy, polarization, rearrangement, and stability of the various bonds of these artificial molecules, anticipated or unanticipated biodegradation may subsequently be followed by novel and unanticipated biointegration. Thus, an advantageous quality in theory may turn out to be disadvantageous in reality. As an example, by 1977 several artificial organosilicon compounds were already known to be capable of serving as the sole energy source for many bacteria.[1] These substrates, when broken down, do not necessarily result in the release of free silicon as an end product. Because such compounds are a carbon source for growth, smaller residual silicon containing molecules may be rearranged and/or redirected for anabolic utilization, with subsequent adverse physiological implications. During

the degradation of these compounds, intermediates can be formed with one or more free Si-O groups, which inherently have a tendancy to react with each other.[1] This chemical reconstitution is not simply the reverse direction of the original degradation. Biological systems are far from homogeneous, and locally concentrated silicon can form polymerized species of unknown crystal forms (i.e., silicates) by interacting with calcium, magnesium, and phosphorus.[1] In this regard, the reported presence of magnesium silicate (talc) in periprosthetic breast tissues may have profound importance, and is worthy of additional study.[3] Talc is a known sclerosing agent, is associated with granuloma formation and chronic inflammation, and may also have adjuvant properties in animal models. Biology can also energize systems, and silicates bound to sugars can become catalytically active, taking on the properties of enzymes.[1] This phenomenon has direct relevance to the reported observation that the sequential evolution of systemic illness following silicone gel-filled breast implantation is unique, & procedes in an exponential manner analagous to a reactor catalysis mechanism.[7] Alternatively, binding of silicates to the sugars of matrix macromolecules could have multiple other profound consequences.

All of the biochemical data discussed thus far have distinct practical significance in light of observations dealing with silicone gel-filled breast implants, including: (1) the documented occurrence of gel bleed through an intact elastomer envelope; (2) the uptake of silicone gel by macrophages and other cells;

(3) the dispersion of silicone gel to multiple distant body sites; and (4) the in vivo breakdown of silicone gel to smaller molecules.[37-43] But these reports also raise more ominous and fundamental considerations, since from the discussion on matrix macromolecules it would appear that there is a finite limit of adaptive mechanisms by which normal cells and tissues can dispose of excess silicon. After that, biochemical chaos affecting synthesis, polymerization, degradation, and recycling of connective tissue components could ensue, with multiple physiological effects. In multiple cohorts of symptomatic breast implant recipients the skin displays a myriad of prominent findings,[6,7,26-35] implying global connective tissue dysfunction of cells and matrix. What is noted on the outside of the body is likely to be diffusely occurring on the inside. Although the incidence of these patients' systemic symptoms and signs needs to be compared to cohorts of device free patients with classical connective tissue diseases, the list of phenomena is long & includes (but are not limited to): fatigue, joint pain, bone pain, dry eyes, dry mouth, dry skin, cognitive dysfunction, myalgia, weakness, hair loss, nail changes, skin rashes, paresthesia, dysesthesia, freckling, pigment change, headache, dizziness, nausea, foul taste, weight gain, weight loss, bruising, photosensitivity, fever, chills, infections in various tissues and organs, loose stools, constipation, periodontal disease, skin papules, muscle twitching, urinary symptoms, dysphagia, menstrual irregularity, blurry vision, tinnitus, drug reactions, emotional lability, insomnia, Raynaud's, edema, hemangiomas, poor wound healing, venous and capillary dilitation and neovascularization (telangiectasias), reduced hearing, reduced smell, tremor, mouth sores, tight skin, dyspnea, wheezing,

palpitations, seizures, parotid swelling, heat intolerance, and cancer.[6,7,26-36] As a logical extension of global matrix dysfunction, and considering the diverse constitutional (genetic) make-up of these patients, such a generalized disease process would be expected to exhibit considerable and variable latency, as well as considerable heterogeneity, two of the hallmarks repeatedly emphasized by multiple investigators reporting on the clinical symptomatology of breast implant recipients. It would also explain the general futility noted in treating patients suffering from suspected silicone toxicity with anti-inflammatory medication, since such a mismatch should come as no surprise, and ought to be expected. Indeed, such patients often exhibit marked intolerance to anti-inflammatory and other medications, probably reflecting metabolic imbalance that leaves little room for normal drug utilization.[6]

The question then arises, is silicone gel-induced disease an extreme form of a more generalized and slower-paced process occurring in the general population? The proliferation of man made silicon containing compounds has raised the exposure level in everyday life considerably. In addition, prior absorption studies of high molecular weight polymeric siloxanes have dealt with urinary excretion studies over days to weeks,[1] and may be fundamentally flawed by not taking into account: (1) the latency of diverse biological processes; (2) the extraction and identification of organosilicon molecules and/or metabolites from biological material is very complicated; (3) the possible degradation of dietary organosilicon compounds by gut bacteria, which may enhance absorption and long

term biointegration; and (4) symbiosis disruption, i.e. the possible interference with the conversion (by gut bacteria) of numerous endogenous and exogenous substrates into a wide spectrum of metabolites (e.g., glycosidases that act on excreted liver products to produce B complex vitamins). Some of these considerations could be studied by applying current knowledge from the rapidly expanding field of geomicrobiology to medicine, which in turn could have important implications for a whole host of medical phenomena and conditions including asthma, colitis, atherogenesis, senile dementia, aging, thrombosis, osteoarthritis, allergy, neuropathy, lupus, myositis, multiple slcerosis, ovarian cysts, fibromyalgia, chronic fatigue syndrome, Sjogren's syndrome, apoptosis, migraines, Alzheimer's, and cancer. One's scientific curiosity can be further enhanced by considering four pieces of knowledge readily available in 1977 encompassing the interface and interaction of silicon containing compounds with organic components of biological systems.[1] One such reaction was the reasonable expectation that acqueous monosilicic acid, $Si(OH)_4$, like the related compounds boric acid, $B(OH)_3$, and germanic acid, $Ge(OH)_4$, would form strong complexes with organic hydroxy compounds such as polyols, saccharides, and hydroxycarboxylic acid. Indeed, the formation of such Si-O-C bonds had been demonstrated to result from the esterification of organic hydroxyl groups with SiOH groups. A second known fact was that in water solution, labile bonds are formed between the neutral oxygen or nitrogen atoms of alcohols, ketones, ethers, amides, and amines and the hydrogen atoms of silanol groups, SiOH. The resulting Si-O-H--C hydrogen bonds

occur with silica particles as well as polysilicic acid, and can result in denaturation of adsorbed proteins due to distortion of the natural molecular conformation. This change in configuration renders the protein unable to fulfill its biological role. Phosphate esters are powerful hydrogen bonding agents, and account for the significant bonding of phospholipids to silica and silicic acid. These observations have direct implications for the interactions of proteins with the fatty acid composition of cell membrane lipid bilayers, thereby potentially adversely affecting membrane permeability, receptors, signal transduction, or other matrix functions. Cell membrane fatty acids exert an antibacterial effect, and are important in maintaining symbiosis between hundreds of bacteria and the epithelium of the oropharynx, vagina, and intestinal tract. Trapping of bacteria in the mucous secretions of the nasopharynx, trachea, and bronchi usually renders the sinuses and lower respiratory tract sterile. Interference with these functions may have significance for the recurrent sinusitis and other infections experienced by implant patients. Thirdly, the chemistry of silicon is much more flexible than that of carbon, as the former behaves at times like a metal and can participate in chelation reactions. An example is the chelation of silicic acid with catecholamines (e.g., dopamine), thereby affecting neurotransmitters. Fourth, polyphosphates (ATP, etc.) are metal ion bound in biological systems, and competition of silicon for phosphorus can occur with resultant silicate-phosphate compounds. The implications for energy production in mitochondria are obvious.

In light of all that has been presented, there clearly are ample new avenues of scientific investigation that can be explored for old diseases, which in turn could simultaneously verify or refute the assertions that silicone gel-filled breast implant induced disease is a novel entity. With the exception of scleroderma, there does not appear to be any rationale for expecting silicone toxicity to translate into well-defined "textbook" medical conditions such as lupus, etc. The tightening and thickening of the skin in idiopathic systemic sclerosis are due to the accumulation of excess collagen and other extracellular matrix constituents, including glycosaminoglycans.[11] Considering that the receptors for fibroblast growth factor and vascular endothelial growth factor are proteoglycans, and considering that one of many sources of growth factors is the mast cell,[11] the circuitous pathogenetic mechanisms of silicone toxicity proposed in this report could easily result in unrestrained fibroblast activation. Resultant features of scleroderma need not necessarily resemble classical subtypes. The controversy over high profiled published studies to date[21,22] that purport to show no association between silicone breast implants and classical connective tissue diseases should not just focus on the analysis of multiple flaws, such as study design, data gathering, exclusions, latency, statistical power, disease misclassification, bias, follow-up, control groups, and mortality contribution.[4] The first pressing notion should be to dispense with preconceived ideas of how patients should get ill. In this regard it is not surprising that many of the immunotoxic mechanisms reported and/or proposed to be operative in symptomatic breast implant recipients have been subjected to a critical and scathing review.[24] Even in classical diseases such as lupus, where

immune dysfunction has clearly been demonstrated, novel studies of biochemical and functional abnormalities of lupus T cells have led to the hypothesis that symptoms and signs of lupus are preceded by an early antigen-nonspecific immune response (9). One of the high profiled studies (22) feebly attempted to insert an afterthought by stating it did not even find evidence for an "atypical" disorder in women with implants. Unfortuneately, many of the common symptoms and signs in symptomatic implant recipients (repeatedly emphasized by numerous investigators) were conspicuously overlooked in this particular aspect of the study. As such, other than the chronological data already referred to (7), appropriate prospective controlled studies demonstrating or denying the existence of a unique silicone-induced syndrome are still lacking.

The diversity of silicon-based products on today's international market is the result of over 100 years of cumulative experience in the synthesis of innumerable organosilicon compounds. Fifty years ago this proliferation coincided with the emergence of biomaterials and bioengineering fields, and was thought to be a fortunate coincidence due to conventional wisdom that polymeric organosilicon compounds (i.e., siloxanes) in the form of high molecular weight silicones were biologically and chemically inert. This "wisdom" was based on observations of the reported chemical resistance of silicones to be degraded by acids and bases as well as resistance to hydrolysis, the small variation in physical properties as a function of temperature, the very low surface tension, the apparent lack of oral absorption of high molecular weight polymeric species, and the relatively mild inflammatory and humoral responses seen with low molecular weight fluids. Indeed, in a published Nobel Symposium held in 1977, researchers from the Dow Corning Corporation were noted to state that "such considerations are among those which have influenced the success of silicones as biomaterials where inertness is absolutely required."[1] However, prior experiments by Dow Corning and others in animals tested with orally administered or injected smaller linear siloxanes, cyclic siloxanes, or polydimethylsiloxane

fluids or gel, revealed pharmacologic and/or toxicologic effects such as estrogenicity, analgesia, hyperalgesia, weight loss, hepatomegaly, decreased release of hypothalamic catecholamines, male gonadal shrinkage, vacuolization of peripheral blood neutrophils and monocytes, chronic organ inflammation (liver, kidneys, pancreas), and systemic migration to lymph nodes, liver, spleen, lung, kidneys, adrenal glands, pituitary, hypothalamus, and ovaries.[1-4,13-17] In addition, an internal Dow Corning report in 1975 examined endotoxin induced interferon type I production in mice after pretreatment with various silicones, including octamethylcyclotetrasiloxane (D4). D4 was shown to have adjuvant activity when mixed with Dow Corning 360 fluid (medical grade silicone fluid, or DC-360, used in humans) in that it substantially augmented the interferon production to endotoxin over that in the controls.[3] This was complemented by another Dow Corning unpublished report in 1974, whereby it was shown that DC-360 had adjuvant effects on humoral immune responses in animals.[3] Yet any mention of these observations by the Dow Corning chemists in the 1977 Nobel Symposium was conspicuously absent, despite discussion of D4 in another experiment detailing its augmentation of catalepsy and ptosis in reserpinized mice.[1] In other words there was the potential for D4 to possibly interfere with monoamine synthesis. A close analogue of D4, Cisobitan, was without significant effect in this same experiment, but two of its isomers were antagonistic to reserpine (possibly by stimulating monoamine synthesis). These experiments highlighted the unexpected activities of cyclosiloxanes, and

demonstrated "pharmacologic actions not predicted from the activity of known pharmacons."[1]

Unfortuneately, in the 1970's these early warning signs did not lead to any large scale studies of the fate of high molecular weight polymeric siloxanes in biological systems, and their half life still remains unknown. Substances were categorized on the basis of intended use, with less consideration for bioavailability, biodegradation, biotransformation, biointegration, or adverse biological activities. It is now clear that high molecular weight silicones (along with the multiple other components, contaminants, and impurities found in breast implant devices) are neither chemically nor biologically inert. In addition to examples already cited throughout this paper, there are reports on (1) local tissue inflammatory and fibrotic reactions to a host of implant materials, including foreign body giant cell granulomas and the presence of numerous cytokines, (2) antibodies to collagen in implant recipients that recognize different epitopes from those seen in patients with SLE or RA, (3) anti-silicone antibodies, (4) T lymphocyte hyper-responsiveness to silica in implant recipients, (5) a higher than expected incidence of antinuclear antibodies in women with breast implants, which increases with duration of implantation and the appearance of systemic symptoms, (6) induction of plasmacytomas by silicone gel in BALB/C mice, (7) diffusion into intact implants of hydrophobic human constituents, such as triglycerides and other lipids, with the potential for immunomodulating liposome-like structures to be formed, (8)the unexpectedly high presence of

subclinical device infections, and their relationship to capsular contracture and clinical complaints, (9) theoretical increased risk of breast cancer in gel implant recipients (with and without polyurethane foam additive), (10) abnormal esophageal motility, and rheumatic complaints with positive ANA tests, in children breast fed by women with implants, (11) morphological and behavioral alterations of fibroblasts by silicone polymers, (12) the demonstration that anti-DNA antibodies from some SLE patients bind to phosphorylated polystyrene, raising theoretical implications for silicone behaving as a specific immunogen leading to cross-reacting immune responses to matrix macromolecules, (13) the association of cancer with silicate fibers (e.g., asbestos), (14) the linkage of silica exposure to systemic lupus and rheumatoid arthritis, (15) other disease entities known to be caused by exposure to crystalline silica dust (e.g., pulmonary fibrosis, nephrotoxicity, scleroderma, macrophage cytotoxicity), (16) the similar reduction of mean plasma serotonin levels in both fibromyalgia patients and symptomatic breast implant recipients compared to normal controls, (17) the increased presence of HLA-DRw53 in both fibromyalgia patients and symptomatic breast implant recipients compared to normal controls and breast implant recipients without symptoms, and (18) the presence of anti-polymer antibodies in both fibromyalgia patients and symptomatic breast implant recipients compared to normal controls.[2-8,10-12,18-20,46]

But there has been a far too narrow focus of investigative direction for both classical and non classical disease states.

The evidence put forth thus far by researchers representing numerous disciplines needs to be sorted out, reassessed, and reanalyzed in light of current knowledge of the fundamental molecular basis of life. Silicase, an enzyme that liberates silicic acid from an artificial organic silicic acid compound, is a membrane bound enzyme found in mitochondria and microsomes of pancreas, stomach, and kidney.[1] Its natural substrate is unknown, but it may have a role in transport function. The silicon content of brain, liver, spleen, lung, and lymph nodes increases with age, and high silicon levels are found in the senile plaques of Alzheimer's dementia (in conjunction with amyloid).[1] The silicon content of aorta, skin, thymus, and hair decreases with age.[1] In other parts of the universe a very different type of silicon chemistry could have occurred if water solutions were replaced with something else. In another world, silicon might still be a requirement for the structural stability of plants, and the fiber contents of grains might still be found to be proportional to their silicon contents. Diseases in that world, however, might have nothing to do with cell-cell and cell-matrix adhesion phenomena. Here on earth these are basic and highly regulated biological processes that permeate every aspect of life. The molecular determinants for these processes are likely to be profoundy affected by excess silicon occurring from the in vivo degradation of breast implant components. This in turn could provide the rationale for predicting the potential toxicity of other organosilicon compounds and simultaneously elicit alternative research endeavors for multiple other disease entities.

BIBLIOGRAPHY

1. Bendz G, Lindqvist I, eds. Biochemistry of Silicon and Related Problems. New York: Plenum Press, 1978.
2. Yoshida SH, Chang CC, Teuber SS, Gershwin ME: Silicon and silicone: theoretical and clinical implications of breast implants. Regulatory Toxicol Pharmacol 1993; 17:3-18.
3. Teuber SS, Yoshida SH, Gershwin E: Immunopathologic effects of silicone breast implants. West J Med 1995; 162:418-425.
4. Yoshida SH, Swan S, Teuber SS, Gershwin ME: Silicone breast implants: immunotoxic and epide miologic issues. Life Sciences 1995; 56:1299-1310.
5. Brawer AE: Clinical features of local breast phenomena in 300 symptomatic recipients of silicone gel-filled breast implants. J Clean Technol, Environ Toxicol, and Occupat Med 1996; 5:235-247.
6. Brawer AE: Clinical features of systemic phenomena in 300 symptomatic recipients of silicone gel-filled breast implants (submitted for publication).
7. Brawer AE: Chronology of systemic disease development in 300 symptomatic recipients of silicone gel-filled breast implants. J Clean Technol, Environ Toxicol, and Occupat Med 1996; 5:223-233.
8. Brawer AE: Amelioration of systemic disease after removal of silicone gel-filled breast implants (submitted for publication).
9. Dayal AK, Kammer GM: The T cell enigma in lupus. Arthritis Rheum 1996; 39:23-33.

BIBLIOGRAPHY
(continued)

10. Sergent JS, Fuchs H, Johnson JS: Silicone implants and rheumatic diseases. In: Kelley WN, Harris ED, Ruddy S, Sledge CB, eds. Textbook of Rheumatology. Philadelphia: W.B. Saunders Company, 1993: Update 4:1-13.

11. Kelley WN, Harris ED, Ruddy S, Sledge CB, eds. Textbook of Rheumatology. Philadelphia: W.B. Saunders Company, 1997.

12. Busch H: Silicone toxicology. Semin Arthritis Rheum 1994; (suppl 1) 24:11-17.

13. Bennett DR, Gorzinski SJ, LeBeau JE: Structure-activity relationships of oral organosiloxanes on the male reproductive system. Toxicol Applied Pharmacol 1972; 21:55-67.

14. Ben-Hur N, Ballantyne D, Rees T, Seidman I: Local and systemic effects of dimethylpolysiloxane fluid in mice. Plast Reconstr Surg 1967; 43:423-426.

15. Ferreira MC, Spina V, Iriya K: Changes in the lung following injections of silicone gel. British J Plast Reconstr Surg 1975; 173-176.

16. Hayden JF, Barlow SA: Structure activity relationships of organosiloxanes and the female reproductive system. Toxicol Applied Pharmacol 1972; 21:68-79.

17. Palazzolo RJ et al: Investigation of the toxicologic properties of a phenylmethylcyclosiloxane. Toxicol Applied Pharmacol 1972; 21:15-28.

BIBLIOGRAPHY

18. Dobke MK, Svahn JK, Vastine VL et al: Characterization of microbial presence at the surface of silicone mammary implants. Ann Plast Surg 1995; 34:563-571.

19. Epstein SS: Implants pose poorly recognized risks of breast cancer. Int J Occup Med Toxicol 1995; 4:315-342.

20. Steenland K, Goldsmith DF: Silica exposure and autoimmune diseases. Amer J Indust Med 1995; 28:603-608.

21. Gabriel SE, O'Fallon WM, Kurland LT, Beard CM, et al: Risk of connective tissue diseases and other disorders after breast implantation. N Engl J Med 1994; 330:1697-1702.

22. Sanchez-Guerrero J, Colditz GA et al: Silicone breast implants and the risk of connective tissue diseases and symptoms. N Engl J Med 1995; 332:1666-1670.

23. Stryer L: Biochemistry. New York: W.H.Freeman and Company, 1995.

24. Marcus DM: An analytical review of silicone immunology. Arthritis Rheum 1996; 39:1619-1626.

25. Campbell A, Brautbar N, Vojdani A: Suppressed natural killer cell activity in patients with silicone breast implants: reversal upon explantation. Toxicol Ind Hlth 1994; 10:149-154.

26. Bridges AJ, Conley C, Wang G, et al: A clinical and immunologic evaluation of women with silicone breast implants and symptoms of rheumatic disease. Ann Int Med 1993; 11*:929-936.

27. Brawer AE: Bones, groans, and silicone: beauty and the beast (abstr). Arthritis Rheum 1994; (suppl)37:R38.

BIBLIOGRAPHY

28. Borenstein D: Siliconosis: a spectrum of illness. Semin Arthritis Rheum 1994; (suppl 1)24:1-7.

29. Solomon G: A clinical and laboratory profile of symptomatic women with silicone breast implants. Semin Arthritis Rheum 1994; (suppl 1)24:29-37.

30. Freundlich B, Altman C., Sandorfi N, et al: A profile of symptomatic patients with silicone breast implants: a Sjogren's-like syndrome. Semin Arthritis Rheum 1994; (suppl 1)24:44-53.

31. Solomon G: Clinical and serologic features of 639 symptomatic women with silicone gel implants: evidence for a novel disease Siliconosis (abstr). Arthritis Rheum 1994; (suppl)37:S423.

32. Davis J, Campagna J, Perrillo R, Criswell L: Clinical characteristics of 343 patients with breast implants (abstr). Arthritis Rheum 1995; (suppl)38:S263.

33. Mease PJ, Overman SS, Green DJ: Clinical symptoms/signs and laboratory features in symptomatic patients with silicone breast implants (abstr). Arthritis Rheum 1995; (suppl)38:S324.

34. Vasey FB, Havice DL, Boranegra TS Seleznick MJ et al: Clinical findings in symptomatic women with silicone breast implants. Semin Arthritis Rheum 1994; (suppl 1)24:22-28.

35. Shoaib BO, Patten BM, Calkins DS: Adjuvant breast disease: an evaluation of 100 symptomatic women with breast implants or silicone fluid injections. Keio J Med 1994; 43:79-87.

36. Shoaib BO, Patten BM: Human adjuvant disease: presentation as a multiple sclerosis-like syndrome. South Med J 1996; 89:179-188.

BIBLIOGRAPHY

37. Peters W, Smith D, Lugowski S, McHugh A, MacDonald P, Baines C: Silicon and silicone levels in patients with silicone implants. Curr Top Microbiol Immunol 1996; 210:39-48.

38. Robinson OG Jr, Bradley EL, Wilson DS: Analysis of explanted silicone implants: a report of 300 patients. Ann Plastic Surg 1995; 34:1-7.

39. Wolf CJ, Brandon HJ, Young VL, Jerina KL, Srivastava AP: Chemical, physical and and mechanical analysis of explanted breast implants. Curr Top Microbiol Immunol 1996; 210:25-37.

40. Goldberg EP: Evaluating the health risks of breast implants (letter). New Engl J Med 1996; 335:1154.

41. Garrido L, Bogdanova A, Cheng LL, Pfleiderer B, Tokareva E, Ackerman JL, Brady TJ: Detection of silicone migration and biodegradation with NMR. Curr Top Microbiol Immunol 1996; 210:49-58.

42. Hardt NS, Emery JA, Steinback BG, LaTorre G, Caffee H: Cellular transport of silicone from breast prostheses. Int J Occupat Med Toxicol 1995; 4:127-134.

43. Schnur PL, Weinzweig J, Harris JB, Moyer TP, Petty PM, Nixon D, McConnell JP: Silicon analysis of breast and peri-prosthetic capsular tissue from patients with saline or silicone gel breast implants. Plast Reconstruc Surg 1996; 98:798-803.

44. Emlen W: Binding of antiphospholipid antibodies to apoptotic cells requires B_2GP1 cofactor. Arthritis Rheum 1996 (abstr); (suppl) 39:S319.

BIBLIOGRAPHY

45. Evered D, O'Connor M, eds. Silicon Biochemistry. Chichester: John Wiley and Sons, 1986.

46. ACR study group: Silicone related syndromes. Arthritis Rheum 1996; (suppl) 39:S25.

AMELIORATION OF SYSTEMIC DISEASE AFTER REMOVAL OF SILICONE GEL-FILLED BREAST IMPLANTS

Arthur E. Brawer, M.D.
Department of Medicine
Division of Rheumatology
Monmouth Medical Center
Third and Pavilion Avenues
Long Branch, New Jersey 07740
U.S.A.

Corresponding author:
Arthur E. Brawer, M.D.
170 Morris Avenue
Long Branch, New Jersey 07740
U.S.A.
(732) ~~(908)~~ 870-3133
FAX: ~~(908)~~ (732) 222-0824

Address for reprints:
Arthur E. Brawer, M.D.
170 Morris Avenue
Long Branch, New Jersey 07740 U.S.A.

Key Words: Silicone; Breast Implants.

Presented in part at the 20th Northeast Regional Meeting of the American College of Rheumatology, June 3-5, 1994, New York City.

SUBMITTED FOR PUBLICATION

ABSTRACT

Aims: To examine the post explantation clinical course in symptomatic recipients of silicone gel-filled breast implants.

Methods: 156 patients who developed a systemic illness following insertion of silicone gel-filled breast implants underwent removal of these devices. Mean implantation time was twelve years, and subsequent follow-up averaged 2½ years.

Results: 76/156 (49%) noted amelioration of their disease starting an average nine months after gel device removal. The occurrence of improvement following explantation was inversely related to the length of time of prior gel device exposure, declining precipitously from 67 percent in those with definitive surgery after only 7½ years implantation time, to 31 percent in those with final surgery after 14½ years. Improvement was unaffected by prior rupture or multiple surgeries, and could not be predicted by age, unilateral implant, or subsets of clinical features. In 112/156 who opted for final gel device removal without saline exchange, ten percent of all improved patients experienced paradoxical and simultaneous disease progression with the appearance of new symptoms and signs. This phenomenon was unaffected by prior rupture, multiple surgeries, or prolonged implantation time, but had a risk nearly five times as great in any of the 44/156 who improved after gel for saline exchange. Transverse rectus abdominis myocutaneous (TRAM) flap surgery performed after final gel device removal was associated with a fifty percent incidence of

panniculitis in the breast areas and/or the abdominal site. Self worth issues, usually via support groups, often needed to be addressed simultaneously with ongoing medical evaluation in order to effect explantation efforts in some seriously ill patients.

Conclusions: In this cohort of symptomatic breast implant recipients, disease amelioration following explantation provides additional supportive evidence for the existence of a novel illness triggered by silicone gel-filled devices. The demonstrated improvement of systemic phenomena following implant removal was more likely to occur if these devices were in place for less than twelve years. Saline implants appeared capable of perpetuating systemic disease progression following an initial gel induced disorder.

INTRODUCTION

The removal of silicone gel-filled breast implants in symptomatic recipients exhibiting a variety of systemic phenomena has been followed by clinical and laboratory improvement in some patients.[1-8,11-13] This is one of many observations supporting the implication that these devices are the cause of a novel illness. In general, post explantation clinical data has been lacking comprehensive analysis of the influence and effects of prior gel exposure time, disease severity, age, multiple prior exchange surgeries, unilateral implant, subsets of clinical features, saline implant replacement, TRAM flap surgery, or prior gel implant rupture. This report attempts to address some of these issues.

MATERIALS AND METHODS

One hundred and fifty-six female patients who developed a systemic illness beginning an average 2½ years after insertion of silicone gel-filled breast implants underwent removal of these devices. The women are part of a larger cohort of 300 patients whose clinical features have previously been described.[9,10] Systemic manifestations, disease severity, and unique chronological evolution were comparable in the two groups as ascertained by a single rheumatologist who interviewed and examined each patient directly.

Mean gel implantation time was twelve years and subsequent follow-up after removal averaged 2½ years, with the latter arranged by either re-examination or telephone contact. Multiple different manufacturing devices were represented in the cohort as a whole. Forty-four patients opted for implant exchange whereby the removal of their gel devices was followed immediately by saline implant replacement.

The definition of improvement included any one of the following four categories: a lessening of the frequency and/or severity of 50 percent or more of the total number of symptoms and signs manifested by a single patient, without requiring complete resolution of any one item, and with the remainder of the patient's symptoms and signs unchanged; a lessening of 50 percent or more of the total number of symptoms and signs manifested by a single patient, despite the appearance of some new symptoms or signs after explantation; a lessening of 50

percent or more despite worsening of other symptoms or signs, but without the appearance of any new symptoms or signs; a lessening of 50 percent or more despite some worsening of others, in conjunction with new symptoms or signs after explantation. As an example, a patient whose systemic disease process encompassed 36 symptoms and signs would have to experience a reduction of the frequency and/or severity of at least 18 clinical features in order to be classified as improved. The definition of unimproved also included one of four categories: unchanged, with prior symptoms and signs no better and no worse, but without new symptoms and signs; unchanged, accompanied by the appearance of new symptoms or signs after explantation; worsening of prior systemic disease features, but without new items; worsening, plus the appearance of new symptoms or signs. All four unimproved categories allow for some simultaneous concomitant reduction in the frequency and/or severity of a few clinical features.

RESULTS

Seventy-six of the 156 patients (49%) noted amelioration of their systemic disease starting an average nine months after gel device removal. The cohort was divided into five groups as noted in table one. Of the 27 patients who underwent removal of their original nonruptured implants, the final surgery was performed an average of $7\frac{1}{2}$ years after implantation (span: 11 months to 18 years). In this group, 18 patients (67 percent) improved, with average follow-up time of 34 months. Improvement began to occur an average nine months after explantation, with the earliest amelioration noted at two months. Two of the 18 patients with improvement (11 percent) developed new systemic symptoms and signs despite their improvement. Of the nine unimproved patients in this category (followed an average 37 months after explantation), one of nine (11 percent) manifested new symptoms and signs. In the improved patients in this category (as well as all the other categories of explantation), a reduction in the frequency and/or severity of individual systemic phenomena was totally random with no specific pattern noted. Similarly, the development of new symptoms and signs in any of the explantation categories, whether improved or unimproved, was also random. The rate of development of new symptoms and signs was invariably much slower than the previously reported time sequence of disease evolution occur-

ring while implants were still in place. Within this group of 27 patients it was not possible to identify any predictive improvement factors such as subsets of clinical features, age, or unilateral versus bilateral implants.

Ruptured original implants were removed in 48 patients. The average time to rupture was 8 1/3 years (span: two years to 21 years), and the average elapsed time from implantation to final surgical removal was 12 years and 10 months (span: four years to 25 years). The longest interval from rupture to final surgery was 13 years. Improvement began an average nine months following final surgery in 21 patients (44 percent), with the earliest reduction of symptoms and signs noted at two months. Two of these 21 patients who improved developed new symptoms and signs (10 percent). Of the 27 patients in this category who were unimproved, eight developed new systemic features (30%). Follow-up time for both the improved and unimproved groups averaged 26 months; no variables allowedprediction of which patients would improve and/or develop new symptoms and signs. Perhaps the most striking finding in this explantation category was that rupture, by itself, did not determine whether or not improvement occurred after explantation. A subgroup of patients was analyzed whose total implantation time was ten years or less (average: 7½ years gel device exposure; average time to rupture: 6¼ years). Sixty-three percent of patients in this subgroup improved, which is comparable to the improvement rate of 67 percent noted in the original nonruptured explantation category. Thus, the length

of time of gel device exposure (but not rupture) determined whether or not improvement occurred following explantation. Further analysis of this same subgroup revealed that one-third of the unimproved patients developed new symptoms and signs. Thus, rupture (but not gel device exposure time) appeared to determine the threefold risk of new symptoms and signs developing in unimproved patients following explantation. Surprisingly, neither rupture nor gel device exposure time influenced the percentage of improved patients who developed new symptoms and signs, which remained constant at ten percent.

Similar pathologic findings were frequently noted in both the rupture and nonrupture explantation groups. As noted in figure one, examination of excised capsules and surrounding tissues beyond the capsule revealed fibrosis and chronic inflammation, the latter including foamy histiocytes, lymphocytic infiltrates, refractile crystalline foreign material consistent with silicone, and foreign body-type giant cells.

The following case history is illustrative of the clinical course before and after explantation. A 33 year old white female, previously in excellent health, underwent bilateral cosmetic breast augmentation with the insertion of silicone gel-filled breast implants. Postoperative breast numbness occurred, followed one year later by bilateral capsular contracture. Two years after implantation she developed headaches, neck pain, and depression. One year later, at the age of 36, abdominal cramps developed along with loose stools and recurrent sinusitis, followed one year later by menstrual

irregularities, fatigue, and pain and swelling in multiple small and large joints. Five years after implantation, at the age of 38, lateral displacement and malposition occurred of the right breast implant accompanied by bilateral bogginess, heaviness, sagging, drooping, and micronodularity. Shortly after, two hours of morning stiffness developed along with recurrent seizures. Seven years from the time of implantation she complained of numbness in her forearms along with dryness of her skin, wheezing, and palpitations. The following year multiple dental cavities occurred along with carpal tunnel syndrome, intermittent blurry vision, and tinnitus. Nine years from the time of implantation, at the age of 42, she developed night sweats which were not alleviated by the institution of estrogen replacement. The following year dysphagia occurred, accompanied by dry eyes and dry mouth, diffuse myalgias, and a gradual 30 pound weight gain. Eleven years from the time of implantation, at the age of 44, she developed recurrent oral ulcerations, intermittent periorbital edema, fevers, and eyelid twitching, followed in one year by chills, dizziness, cognitive dysfunction, and rib pain and tenderness. Fourteen years after implantation a CT scan of the brain was negative, and multiple lab tests including chemistries, CBC, sed rate, and ANA were normal or negative. By this time, cracking and splitting of her nails had occurred along with bilateral greenish-black breast discharge, diffuse skin itching, and a skin rash. Later that same year bilateral ruptured implants were removed, without

replacement. Three months after explantation, at the age of 48 (and extending over the next 24 months), she began to notice gradual improvement (but by no means resolution) of her polyarthritis, morning stiffness, palpitations, night sweats, chills, dizziness, weight gain, depression, loose stools, abdominal cramps, dysphagia, fevers, sinusitis, eyelid twitching, periorbital edema, rib pains, tinnitus, forearm numbness, wheezing, headaches, mouth sores, and neck pain. Current physical examination at the age of 50 reveals anterior chest wall telangiectasias, vitiligo, and freckling; a positive Phalen's sign; a Schirmer test exhibiting 0 mm of tear formation; parotid swelling; and palmar erythema.

The third category in table one includes eight patients who have undergone insertion and/or exchange of multiple sets of silicone gel-filled breast implants, with no documented ruptures, followed by final gel device removal. The average total implantation time was 8 3/4 years (span: three years to 17 years), and the longest set of implants remained in place for nine years. The entire group has an average 28 month follow-up, but the number of patients in this category is too small for adequate analysis.

Twenty-nine patients had multiple sets of silicone gel-filled breast implants inserted and/or exchanged, with at least one rupture. Gel exposure time (initial implantation to final surgery) averaged 14½ years (span: 3 years to 22 years), and the average time to rupture was 6 2/3 years (span: 2 months

to 16 years). Nine patients (31 percent) experienced improvement beginning an average of ten months after final explantation, with the earliest improvement noted at four months. One of the nine (11 percent) developed new symptoms and signs. Of the 20 patients who remained unimproved, five (25 percent) developed new symptoms and signs. Follow-up time averaged 28 months for both improved and unimproved patients, and prior observations of the lack of predictable variables were also noted. Within this explantation category was a subgroup of patients with final surgery 16 years or less (average 13 years) from the time of initial implantation. Forty percent of this subgroup experienced improvement in their clinical features, which is comparable to the improvement rate of 44 percent (noted at 12 years and ten months) in the category of original ruptured explanted devices. This analysis reinforces the finding that the length of time of gel device exposure (but not rupture) determined whether or not improvement occurred following explantation.

The following case history is illustrative. A 26 year old white female developed postpartum breast atrophy after an uncomplicated pregnancy. One year later she underwent bilateral breast augmentation with the insertion of silicone gel-filled breast implants. Itching in both breasts occurred within one month, followed by capsular contracture in another month. Four closed capsulotomies afforded no help with the breast pain and hardening. One year after implantation, at the age of 28, a rash appeared on the trunk accompanied by recurrent urinary

tract infections and leg edema. That same year implant exchange was performed for another set of silicone gel-filled breast implants due to severe pain with the first set. Capsular contracture recurred in one month and was not helped by two closed capsulotomy procedures. One year later, at the age of 29, hair loss, fatigue, nausea, and weight loss occurred, accompanied by anterior chest pain and myalgias over the next three years. Eight years after the very first augmentation, at the age of 35, bilateral breast nodules developed; excision of one of these revealed silicone granuloma. Mammography was positive for bilateral rupture. Six more years elapsed, during which she developed livedo reticularis, polyarthritis, dry eyes and dry mouth, one hour of morning stiffness, periorbital edema, headaches, and leg varicosities. Sixteen years after the first implantation, at the age of 43, she underwent implant exchange for a third set of silicone gel-filled breast implants. At the time of surgery it was noted that there was "gel all over the place." Capsular contracture recurred within one month. One year later diffuse skin freckling developed, accompanied by cognitive dysfunction and dysesthesias in the extremities. Within a few months she underwent another implant exchange for a fourth set of silicone gel-filled implants, and at the time of surgery it was noted that the third set of gel implants had previously ruptured bilaterally. Two years later, at the age of 46, she developed diffuse telangiectasias on the anterior chest wall, and splotchy hyperpigmentation on the face and trunk.

At that time a Schirmer test was recorded as 0 mm. Twenty-one years after her initial augmentation, at the age of 48, her fourth set of implants was removed without replacement; at the time of this surgery one implant was noted to have previously ruptured. Within four months she developed chills, dyspnea on exertion, muscle weakness (with only a marginal elevation of CPK), erythema on the chest wall in a V-neck distribution, and dizziness. Current evaluation 24 months after her final explantation reveals no improvement in any of her systemic symptoms and signs.

The psychological and social issues confronted by these women prior to explantation were considerable. Despite deteriorating health coupled with participation in support groups, the overriding factor in many of these women was the vision of post-explantation physical deformity, an example of which is seen in figure 2. This prompted 44 women to undergo immediate replacement with saline implants at the time of their final gel implant removal. Total gel device exposure time prior to saline exchange averaged 10½ years (span: 2 years to 25 years). Twenty-six of the 44 patients (59%) experienced improvement of their systemic illness. Thirty-five of the 44 had one or more ruptures from one or multiple prior sets of gel implants, which proved to be equally divided between improved and unimproved groups (81 percent and 78 percent respectively). Similarly, there were no subgroup differences in disease severity, clinical features, age, unilateral versus bilateral

devices, prior gel implantation time, time to rupture, and saline implantation time (average $2\frac{1}{2}$ years; span 8 months to $7\frac{1}{4}$ years). In the improved group, the average elapsed time from the saline exchange surgery until lessening of disease occurred was ten months.

The most striking finding in the saline exchange group was the marked incidence of new symptoms and signs, which was noted in 12 of the 26 patients (46%) who had exhibited improvement in their prior gel-related illness. Since both rupture and gel exposure time had no influence on the appearance of new phenomena in all improved groups of patients in any other explantation category, the difference noted (46 percent versus 10 percent) has to be related to the saline implant itself. Of the unimproved saline exchange patients, 13/18 (72 percent) developed new clinical features. Since rupture (but not gel exposure time) altered the occurrence of new symptoms and signs in unimproved patients after explantation, the difference noted (72 percent versus 30 percent) has to be related to the saline implant itself. Within these saline exchange subgroups, the average elapsed time to the development of new phenomena was ten months (span: 2 months to 24 months), saline implantation time was comparable, and 13 of the 25 with new features exhibited a brand new skin rash of one type or another.

The following case history is illustrative. A 20 year old white female underwent bilateral cosmetic breast augmentation with the insertion of silicone gel-filled implants. Within one week both breasts became numb and itchy, and three months

later fatigue and right axillary lymphadenopathy developed, accompanied by bilateral capsular contracture (the latter unimproved after one closed capsulotomy). One year after implantation the right breast developed puckering, rippling, and dimpling; shortly thereafter she complained of dry skin, confusion, depression, nausea, epigastric pain, abdominal bloating, and arm tremors. Three years after her surgery, at the age of 23, several lumps developed in the right breast. This was accompanied by dry eyes and food allergies to milk and wheat. Two years later increased breast itching occurred along with diffuse myalgias, which was followed by slow shrinkage of both breasts over the next five years (from a size 36C bra to a size 36A). During this period of shrinkage, at the age of 28 (or eight years following implantation), she developed pain and swelling in multiple small and large joints, hoarseness, night sweats, dizziness, metallic taste, two hours of morning stiffness, anterior chest pain, hair loss, and a weight gain of 29 pounds. The next year tinnitus appeared along with photosensitivity, neck lymphadenopathy, and palpitations. Ten years after her augmentation, at the age of 30, she underwent removal of bilateral ruptured implants, followed by the immediate insertion of saline breast implants. Two years later she developed the new onset of menstrual irregularities, poor wound healing, and periorbital edema. At the age of 33 she began to notice gradual slow improvement (but by no means resolution) of her chest pain, arthritis, photosensitivity, palpitations, tinnitus, neck lymph-

adenopathy, night sweats, dizziness, hoarseness, metallic taste, hair loss, myalgias, nausea, tremors, epigastric pain, and abdominal bloating. Five years after saline exchange, at the age of 35, she developed the new onset of dysesthesias in her fingers and headaches, followed one year later by recurrent sore throats, dysphagia, and a papular erythematous rash on the extremities (unrelated to sun exposure). At age 37 an ANA was positive in a titre of 1:160 in a speckled pattern, and a Schirmer test was 8 mm; other lab tests (chemistries, thyroid function, CBC, etc.) were normal, and her clinical condition remained unchanged.

Table 2 summarizes the improvement data for all explantation groups that were analyzed. Graphic illustration of the results is shown in figure 3. As the length of time of gel device exposure increased, the percentage of improved patients decreased.

Ten of the 156 patients underwent TRAM flap surgery after final removal of their gel-filled implants (average implantation time ten years). An example of this is noted in figure 4. Five patients (50 percent) developed panniculitis (subcutaneous fat necrosis) in the breast areas and/or the abdominal site, which is five times the expected incidence in non symptomatic individuals without gel device exposure. No predisposing factors could be identified such as malignancy, unilateral implant, prior rupture, or multiple implant exchanges.

DISCUSSION

This report of 156 symptomatic breast implant recipients who underwent explantation revealed a declining occurrence of systemic improvement with increasing duration of gel device insertion. The best chance for disease amelioration was noted when implants were removed on average no later than 7½ years after insertion. Shorter implantation time of less than five years did not yield better results. These observations are complementary to prior findings in the entire cohort of 300 in whom increasing severity of systemic illness was directly related to the length of time of gel device exposure.[9] Taken together, the sicker that patients became from their silicone-induced illness, the less likely they were to improve after removal of these devices.

Improvement began an average nine months after implant removal, was unaffected by prior rupture or multiple surgeries, and could not be predicted by age, unilateral implant, or subsets of clinical features. In patients without saline exchange, improvement was accompanied by a ten percent occurrence of paradoxical and simultaneous disease progression characterized by the appearance of new symptoms and signs. This implies that residual mechanisms of silicone-induced disease causation continued to be operative despite a natural attempt by the body to heal itself following bulk device removal. This phenomenon was unaffected by prior rupture, multiple surgeries, or prolonged implantation time, but had a risk nearly five times as

great in any of those who improved after gel for saline exchange. Since the elastomer, or envelope, of a saline implant is similar to the envelope of a gel implant (i.e., both are solid silicone), in some patients already sensitized with a gel-induced illness further exposure to analagous devices proved to be deleterious. This risk increased seven-fold in any of those who were unimproved after gel for saline exchange. The significance of rupture (in the absence of saline exchange) was confined to a three-fold risk of disease progression in unimproved patients.

Except for nonsteroidal anti-inflammatory drugs and/or analgesics, the essential cornerstone of managing systemic illness was the surgical removal of the silicone gel-filled breast implants. Verification of the results in figure three will require analysis of other groups of symptomatic implant recipients. In addition, the 12 years of gel-induced disease development will ultimately need to be balanced by a comparable observation period after explantation to help determine whether silicone-induced disease can persist indefinitely. If these results are sustained, it does not bode well for the remaining 144 patients (from the original cohort of 300) in whom silicone gel-filled devices remain implanted over an average 14 1/3 years (longest 27 years). Of these 144 patients, 79 (55 percent) presently have a ruptured implant in place, and when placed on the curve in figure 3 can be expected to have less and less chance of improvement (and a corresponding increased risk of disease progression) despite future anticipated

explantation. In many of these patients, a lack of adequate health insurance coverage is one of many factors adding to the delay in surgical removal.

Improvement data in this report were not evaluated or adjusted for time to disease onset, as the numbers of patients were too small to permit such an analysis. Instead, the average disease onset of $2\frac{1}{2}$ years after implant insertion was utilized. It may well be subsequently shown that the explantation improvement curve noted in figure 3 shifts to the right for a later disease onset. As an example, a patient with 15 years total implantation time, whose silicone-induced illness did not begin until 10 years from the time of original insertion, might be expected to have a 67 percent chance of improvement (based on five years of systemic disease activity) instead of less than 30 percent chance of amelioration (based on total implantation time). For this latter premise to be proven correct, it would mean that increasing latency of systemic disease onset has a favorable effect on the chance of improvement following explantation. Superimposed on this are potential treatment variables, such as dietary inclusions or exclusions, exercise, metabolic supplements and alterations, pharmacologic regimens, or other innovative interventions. Any treatment modalities claiming long-term success for disease amelioration must be measured against the natural course of the illness.

In summary, the findings in this cohort of symptomatic breast implant recipients provide supportive evidence for the

existence of a novel illness triggered by silicone gel-filled devices. The chance of clinical improvement following explantation was inversely related to the length of time of prior gel device exposure. These results are directly complimentary to previously reported disease development data,[9] and strengthen the recommendation that advice given to symptomatic patients for implant removal should be based primarily on the total duration of implantation and not whether implants are thought to have ruptured. The risk of gel for saline exchange is in need of further assessment as this was capable of perpetuating systemic disease progression in patients already demonstrating established silicone gel toxicity.

EXPLANTATION

156/300

Five Categories

ORIGINAL NON RUPTURED GEL	27/156
ORIGINAL RUPTURED GEL	48/156
MULTIPLE GEL SETS, NO RUPTURES	8/156
MULTIPLE GEL, AT LEAST 1 RUPTURE	29/156
GEL EXCHANGE FOR SALINE	44/156

Table 1 Patients who underwent final silicone gel-filled breast implant removal.

IMPROVEMENT AFTER EXPLANTATION

GEL EXPOSURE (YEARS)		PERCENT IMPROVED
7½	ONR	67%
10½	SAL	59%
12⅚	ORP	44%
14½	MRP	31%

ONR = ORIGINAL NON RUPTURED GEL

SAL = GEL EXCHANGE FOR SALINE

ORP = ORIGINAL RUPTURED GEL

MRP = MULTIPLE GEL SETS, AT LEAST ONE RUPTURE

Table 2 Percentage of patients experiencing improvement of their symptoms and signs after final gel implant(s) removal.

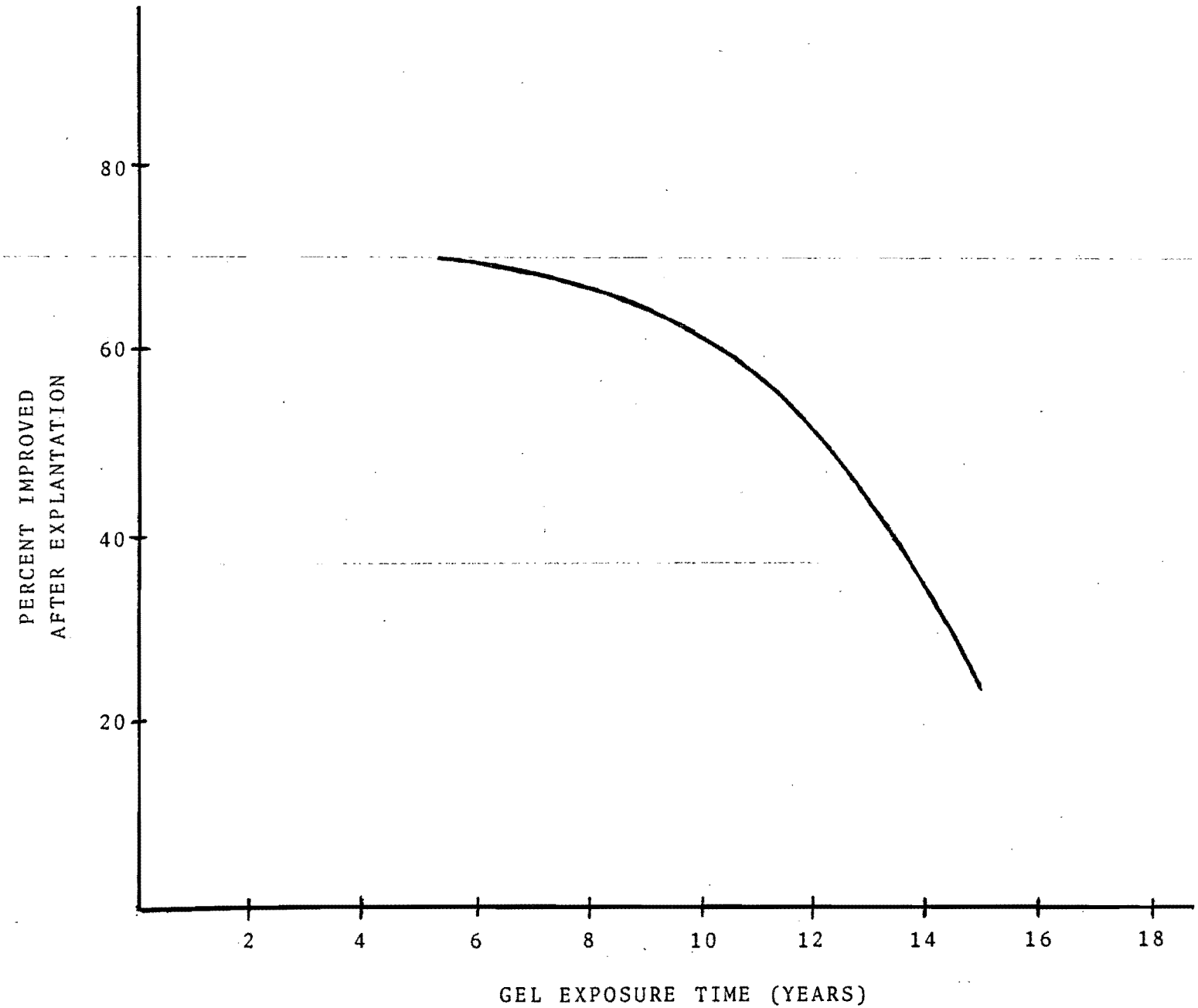
80
60
40
20
PERCENT IMPROVED
AFTER EXPLANTATION
2
4
6
8
10
12
14
16
18
GEL EXPOSURE TIME (YEARS)

FIGURE 3

LEGENDS FOR FIGURES

Figure 1: Silicone, or foreign body giant cell, granuloma.

Figure 2: Appearance of a 37 y.o.w.f. after final explantation of bilaterally ruptured silicone gel-filled implants.

Figure 3: The explantation improvement curve. The chance of realizing amelioration of systemic symptoms and signs following final implant(s) removal was inversely related to the length of prior gel exposure (i.e., total implantation) time.

Figure 4: A 49 y.o.w.f. six months after simultaneous final removal of gel implants and reconstruction by TRAM flap surgery (see text).



1

2

4



BIBLIOGRAPHY

1. Kaiser W, Biesenbach G, Stuby U, et al: Human adjuvant disease: remission of silicone-induced autoimmune disease after explantation of breast augmentation. Ann Rheum Dis 1990; 49:937-938.
2. Vasey FB, Havice DL, Boranegra TS, Seleznick MJ et al: Clinical findings in symptomatic women with silicone breast implants. Semin Arthritis Rheum 1994; (suppl 1)24:22-28.
3. Cuellar ML, Espinoza LR, Ochs R, Tan EM: Clinical outcome of silicone breast implant women following implant removal (abstr). Arthritis Rheum 1995; (suppl)38:S264.
4. Campbell A, Brautbar N, Vojdani A: Suppressed natural killer cell activity in patients with silicone breast implants: reversal upon explantation. Toxicol Ind Hlth 1994; 10:149-154.
5. Sahn EE, Garen PD, Silver RM, Maize JC: Scleroderma following augmentation mammoplasty: report of a case and review of the literature. Arch Dermatol 1990; 126:1198-1202.
6. Gutierrez FJ, Espinoza LR: Progressive systemic sclerosis complicated by severe hypertension: reversal after silicone implant removal. Am J Med 1990; 89:390-392.
7. Spiera RF, Gibofsky A, Spiera H: Immunological reactions to silicone implants. Clin Immunother 1994; 1:406-412.
8. Brawer AE: Bones, groans, and silicone: beauty and the beast (abstr). Arthritis Rheum 1994; (suppl)37:R38.

BIBLIOGRAPHY

9. Brawer AE: Chronology of systemic disease development in 300 symptomatic recipients of silicone gel-filled breast implants. J Clean Technol, Environ Toxicol, Occup Med 1996; 5:223-233.

10. Brawer AE: Clinical features of local breast phenomena in 300 symptomatic recipients of silicone gel-filled breast implants. J Clean Technol, Environ Toxicol, Occup Med 1996; 5:235-247.

11. Svahn JK, Vastine VL, Landon BN, Dobke MK: Outcome of mammary prostheses explantation: a patient perspective. Ann Plastic Surg 1996; 36:594-600.

12. Baker MF: Treatment of silicone implant associated symptoms (abstr). Arthritis Rheum 1996; (suppl) 39:S51.

13. Vasey FB, Aziz N, Havice D, Wells AF: Prospective clinical status comparison between women retaining gel breast implants vs. women removing implants (abstr). Arthritis Rheum 1996; (suppl) 39:S52.

File Breast Reconstruct

DebCar Publishing

President
Pamela Stott-Kendall
P. O. Box 030153
Fort Lauderdale, Florida 33303

Telephone: (954) 563-1215; Fax: (954) 467-3882
Order: (800) 355-9590; E-mail: debcarpub@aol.com
Internet: http://www.bookworld.com/debcar

June 12, 1997

Mr. Chris Jennings
Deputy Assistant to the President for Health Policies
Old Executive Office Building, Room 216
1700 Pennsylvania Avenue
Washington, DC 20502
Fax: (202) 456-5557
Pages: 6

Dear Mr. Jennings,

Diane Griffith, the congressional liaison of a national and international silicone-support organization, USSW, spoke with your assistant today, regarding a requested appointment, and was asked to fax an agenda of concerns to be discussed during a future meeting. The subject of our main topic relates to an urgent, growing need of a Federal Task Force on Silicone Implants, as specified in a March 18 *Letter to Congress.* In support of this concern, several United States Representatives are now writing a congressional, White House petition, calling for such a working task force. Though I had earlier forwarded a copy of the authored *Letter to Congress*, along with summaries of important, governmental meetings recently attended, I re-submit the congressional letter.

As I will return to Washington during the week preceding a June 26, afternoon meeting with Director Blumenthal of the Office for Women's Health, Public Health Service (and a morning taping of Dr. McLaughlin's television program, *One on One*), an appointment scheduled in that general time-frame would be greatly appreciated. We also have an appointment pending with Deputy Secretary Kevin Thurm, Department of Health and Human Services.

I thank you for your willingness to discuss this serious health crisis, affecting, literally, hundreds of thousands, upon thousands, of Americans as well as an unborn generation of children.

Cordially,

Pamela S. Kendall

Pamela Stott-Kendall

LETTER TO CONGRESS

Statement of Legislative and Governmental Relief for Silicone-Implant Recipients

Prepared for:
Jan Erickson
National Organization for Women
1000 16th Street, Suite 700
Washington, DC 20036

Prepared by:
Author Pamela Stott-Kendall, *Torn Illusions*
(Reference: *Torn Illusions* has been accepted by the Food and Drug Administration for inclusion in the FDA Center for Devices and Radiological Health Library.)
Diane Griffith, congressional liaison for United Silicone Survivors of the World (USSW)

March 18, 1997

Introduction:

Silicone implantation represents a forty-year period of human experiment without governmental or legislative intervention and regulation having required: 1) proof-of-safety submissions from manufacturers (in 1991, silicone-gel breast implants failed to prove safe when industry safety-data was finally demanded and reviewed by the Food and Drug Administration, FDA), 2) supervised clinical testing, 3) epidemiological research study, 4) and, more recently, the study of currently-injured implant recipients. To date, through the FDA's mandatory Manufacturer Device Reporting (MDR) program, silicone-gel, breast implant manufacturers have reported over 115,000 injuries and illnesses and close to 100 deaths; these MDR statistics increase at a rate of several thousand, new reports of breast implant-associated injuries and illnesses, along with several, new reports of associated death, each and every month. Despite documentation of continually-rising numbers of women harmed, and despite documentation of similar injuries, illnesses and deaths having occurred in relationship to all silicone implants of different form and use, none of these other silicone devices have undergone FDA review nor scrutiny of industrial proof-of-safety data.

In face of silicone's ongoing, unregulated human experimentation and on behalf of more than thirteen-million Americans, including women and men, who are recipients of various implanted silicone devices, and in further protection of their children exposed to second-generation silicone risks, we ask and recommend that the following congressional and governmental initiatives be introduced and implemented.

Governmental Initiatives to be Enacted:

1. Federal Task Force comprised of:

A. Knowledgeable medical experts who satisfy criteria restricting special-interest affiliation and who have conducted independently-funded, peer-reviewed, published silicone research.

B. Steering Committee of injured, silicone breast-implant recipients who represent the established goals of silicone informational and support networks.

C. Federal agency representatives of the National Institute of Health, Food and Drug Administration (FDA Center for Devices and Radiological Health and Office of Consumer Affairs), Health and Human Services, Center for Disease Control and Social Security Administration.

D. Representatives of major health-insurance providers.

2. Immediate guidelines set and action taken, with punitive measures adopted, by appropriate federal agencies (Federal Communication Commission and/or Food and Drug Administration) to effectively monitor, as well as to enforce, existing regulations that prevent circulation of misleading and false advertisement relating to silicone-implant use and safety.

3. Patient registry be formed to thereby total and track all silicone implant recipients, including supervised follow-up of the long-term effects of silicone implantation, pertaining, but not limited, to local, systemic, immune and neurological complications. Information collected may be utilized to establish disease-criteria relevant to silicone illness: a specific, unprecedented syndrome encompassing chronic inflammation, autoimmune/connective-tissue disorder, neurological involvement and toxic reaction that, as a syndrome, is typified by unique, yet undefined combinations of symptoms, clinical observations, laboratory findings, systemic organ/gland damage and immune dysregulation.

4. Adequate federal funding for silicone research be allocated to University-associated rheumatologists, immunologists, neurologists, toxicologists, oncologists, endocrinologists and pediatricians who satisfy criteria restricting special-interest affiliation. By this restrictive criteria, plastic surgeons, either individually or as group-organizations, will not receive federal research-funds; in addition to special-interest considerations, plastic surgery is not a diagnostic field of medicine.

5. Public-health campaign to disperse factual information on known complications and risks of silicone implantation be implemented by: 1) Health and Human Services, 2) U. S. Public Health Service, 3) Center for Disease Control, 4) and any other federal agency serving public education. For example, the public has not been informed of the FDA's own statistics stating that 71% of all breast implants rupture, or show severe gel-bleed/leakage, within ten years; 95% of these devices rupture within fifteen years, and gel-leakage occurs in 100% of all gel-filled devices from day-one of implantation. A public-health campaign, supported by these federal agencies, shall also initiate an educational program to benefit members of the medical community, in particular, those individual physicians who treat implant patients on a regular basis.

6. Due to unacceptable device failure and complication rates, the silicone-gel, breast implant ban (1992 FDA restriction of general market) shall remain in effect permanently. Recent research, (conducted by Mayo Clinic/Department of Health Sciences/Division of Rheumatology and Internal Medicine/Division of Plastic Surgery) published in the *New England Journal of Medicine* on March 6, 1997 (Vol. 6, no.10, pp. 677-719), supports a restriction of gel-fill, breast

implantation. In this study, 25% of women (one in four) who received these devices required additional breast-surgery due to complications occurring within five years of initial implantation. In cancer patients after mastectomies, breast-implant complications are three times more likely to occur than in cosmetic patients.

7. Continuation of Social Security, Welfare and Medicare/Medicaid benefits for silicone-related medical disabilities stemming from "toxic effects of silicone" as allowed by the ICD-9-CM classification system.

8. To reflect accurate statistics, research and data compiled by the FDA, the agency shall update and revise Consumer publications, currently being distributed to the prospective and current implant recipients, to provide all known information on silicone breast-implant risk.

Legislative Initiatives to be Enacted:

1. House Bill 366, written by United States Congressman James A. Traficant, Jr., of Ohio, cited as the "Breast Implant Accountability Act" to "require the surgical removal of silicone gel and saline fill breast implants, to provide for research on silicone and other chemicals used in the manufacture of breast implants."

A. Explantation: Manufacturers shall pay all related medical, surgical and hospital costs of surgical removal of breast implants; explant patient may choose the physician and hospital of choice; the surgically-removed implant is the property of the explant patient; public notification "shall be published in national publications and newspapers of general circulation."

B. Follow-up care and treatment of complications: Manufacturer is responsible for "post-operative care and treatment, including subsequent surgery to remove residual silicone, scar capsules, and granulomas, mammograms, and medication."

C. Research shall be conducted, or contracted to be conducted, by the Secretary of Health and Human Services to determine the "physiological, neurological, and immunological effects of silicone toxicity and toxicity of other chemicals found in, or used in the process of manufacturing, breast implants."

D. Informed consent: Physicians may not perform an implantation unless the prospective patient has first signed a consent form, prescribed by the Secretary of Health and Human Services, stating that the prospective patient has been informed of "all health risks associated with silicone oil, silica, and other chemicals used in the manufacturing of breast implants.

E. Physician services: A physician shall not refuse to treat a patient because that patient is a breast-implant recipient.

F. Organ and blood donations: "The Secretary of Health and Human Services may not make a grant... to an organ procurement organization if such organization has allowed an individual who has a breast implant in their body to donate an organ of the individual's body"; "the Secretary of Health and Human Services may not license any entity engaged in the

collection of blood ... if such entity receives blood from an individual who has a breast implant in their body."

2. Additional legislative protection is sought to provide health-insurance coverage, without exclusion or policy cancellation, pertaining to local and/or systemic adverse effects of silicone implantation relating to both cosmetic and reconstruction surgery.

As manufacturers fight to limit financial responsibility, and lessen settlement or court awards, to injured, silicone-implant recipients through industry litigation and bankruptcy pleadings and while health-insurance providers cancel and amend policies to exclude and/or deny silicone-related coverage, thousand upon thousands of silicone ill women, and men, turn to government-assisted support programs. FDA consultant and John Hopkins physician Dr. Norman Anderson has stated estimates projecting that 133 to 169 billion dollars will be needed for the monitoring, management and rehabilitation of breast implant victims residing in the United States alone. In time, public outcry and outrage will reach Congress; the number of silicone ill people who, after losing employment and health-insurance benefits, must rely upon government-assisted programs, both for support and medical care, grows at an alarming rate (MDR statistics). Research presented during a March, 1995 Immunology of Silicone Workshop, sponsored by the National Institute of Health, stated additional estimates projecting that less than 300,000 of an approximate, two-million American women with breast implants have reached the period of high risk for developing silicone-related disease. The FDA has acknowledged a seven to fifteen-year period of latency before symptoms and signs of implant-related illness surface.

3. Due to an established seven to fifteen-year period of disease latency associated with the development of silicone-related illness, current "statue of limitations" time-restriction on court case-filings and the discovery process, as applicable to product-liability litigation, must be revised and extended on both state and federal levels. Appropriately, in the state of New York, courts have waived "statute of limitations" restriction applicable to breast implant-related legal actions.

4. To ensure that equal distribution of financial burden rests upon those parties held responsible and not solely be delegated to governmental assistance at the public's expense, Congress must address the larger issue of securing just compensation for injured, silicone implant recipients.

5. S. 224, written by Senator Herbert H. Kohl of Wisconsin, cited as the "Sunshine in Litigation Act of 1997," to "amend chapter 111 of title 28, United States Code, relating to protective orders, sealing of cases, disclosures of discovery information in civil actions, and for other purposes."

A. Protective orders and sealing of cases/settlements relating to public health and safety: An order under rule 26 (c) of the Federal Rules of Civil Procedure, restricting the disclosure of information, must not restrict the disclosure of information which is relevant to public health or safety; or "the public interest in disclosure of potential health or safety hazards is clearly outweighed by a specific interest in maintaining the confidentiality of the information or records in question"; "the requested protective order is no broader than necessary to protect private interest."

B. Duration: No order entered in accordance with this protective provision shall continue in effect after the entry of final judgment, "unless at or after such entry the court makes a separate particularized finding of fact that the requirements" of amendments (paragraphs 1, A or C) have been met; the party seeking the entry of an order carries the burden of proof in obtaining such an order.

C. "No agreements between or among parties in a civil action filed in a court in the United States may contain a provision that prohibits or otherwise restricts disclosure of relevant information to any Federal or State agency with authority to enforce laws regulating an activity relating to such information"; information disclosed to a Federal or State agency, as described, "shall be confidential to the extent provided by law."

D. As to evidence of serious public-health consequences resulting from a long history of court-protection of documents held secret despite warnings of health risks affecting the general public, the 1984 Stern versus Dow Corning case in California is a prime example. Attorney Dan Bolton, who represented the plaintiff, testified before a 1988 FDA Advisory Panel Review:

> "I can tell you, however, that the jury saw many of these documents and determined that DOW had committed fraud, mislead the public, and disregarded the safety of women in marketing silicone breast implants. The judge in the Stern case described the Dow's conduct as, quote, 'highly reprehensible.'"

6. In closing, we ask that a congressional investigation and full hearing be held into the accountability of Dow Corning, Dow Chemical, Baxter Healthcare, Bristol Myers-Squibb and other silicone-implant manufacturers.